



**Patient's Name:**

**Date of Birth:** 01/01/2010

**Date of imaging study:**

**Date of Report:** 09/11/2024

**Requesting practice:**

**Purpose of the study:** Pathology

**Relevant Notes and History:** Please evaluate lesion in the area of missing #17

**Pertinent Medical, dental history and any relevant medications:**

---

**Radiographic Technique:**

- The provided imaging study is a large FOV CBCT volume capturing maxillary and mandibular dental arches.

**Area of Interest:**

- There is a well-defined, unilocular, partially corticated, minimally expansile low-density lesion in the left posterior mandible distal to #18 extending up to the anterior ramus involving edentulous site #17, buccolingually involves the complete bone width and supero-inferiorly, extends from the anterior ramus, alveolar crestal region of site #17, to inferiorly close to the inferior border.
- Thinning and mild expansion of the alveolar crestal region and lingual cortex, buccal cortex appears intact, with slight scalloping near the superior buccal aspect.
- There is possible approximation of the lamina dura of distal root of #18 from cervical to apical aspects, with no appreciable signs of resorption/displacement.
- There is possible involvement of the inferior alveolar canal, thinned cortices noted anteriorly and posteriorly to the lesion but intact.

**Dento-alveolar and Osseous Structures:**

- Missing teeth: #17
- #1, 16 and 32 are present, developing, negative for radiographic signs of associated osseous pathology.
- Generalized bone levels are approaching the cervical third.

**Nasal Cavity:**

- Mild nasal septum deviation to the left side, intact borders.



**Paranasal Sinuses:**

- Visualized maxillary sinuses show minimal peripheral mucosal thickening with intact borders and patent ostiomeatal complex bilaterally.

**Airways:**

- The pharyngeal airway spaces appear patent, minimum upper airway cross-sectional dimensions within normal radiographic limits.
- Mild-moderate adenoidal and palatine tonsillar hypertrophy bilaterally and symmetrically.

**Temporomandibular Joints (TMJs):**

- Right and left TMJs: Condylar volume, thinned cortical outlines, morphology and temporal bone components are within normal radiographic limits.
- Condyle-fossa relationship: Right condyle is slightly posteriorly positioned in the glenoid fossa, left condyle shows adequate radiographic spaces.

**Cervical Spine:**

- Mild osseous remodeling changes with the visualized aspects.

**Radiographic Impression and Recommendations:**

- Left posterior mandible, site #17: Radiographic findings are indicative of a **benign cystic process, most likely simple bone cyst vs odontogenic keratocyst (OKC):**
- correlate with clinical history/findings, and biopsy/histopathological correlation is advised for definite diagnosis, biopsy should initiate healing process if it is simple bone cyst or confirm the diagnosis of other cystic lesions such as OKC which will require appropriate management/intervention.

Thank you for the opportunity to serve your practice,

Sincerely,

**Mayank Pahadia (BDS, MDS, MS)**

Diplomate, American Board of Oral and Maxillofacial Radiology

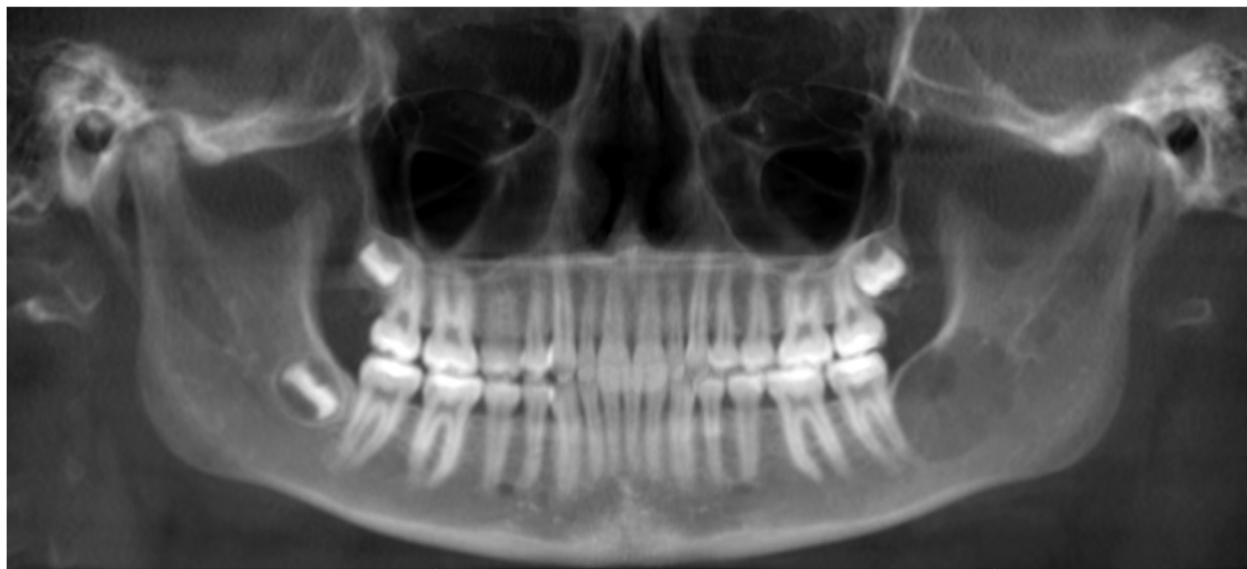Consultant Oral and Maxillofacial Radiologist

Contact: (904) 430 5010

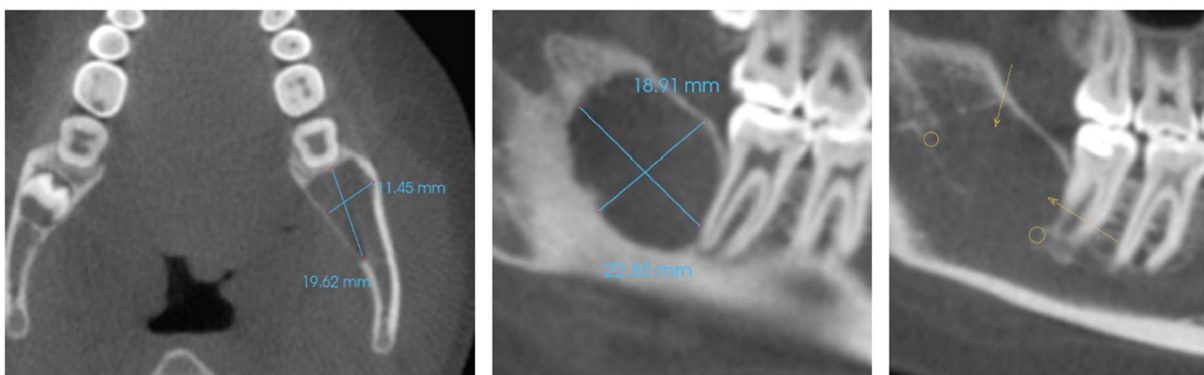


**Disclaimers:**

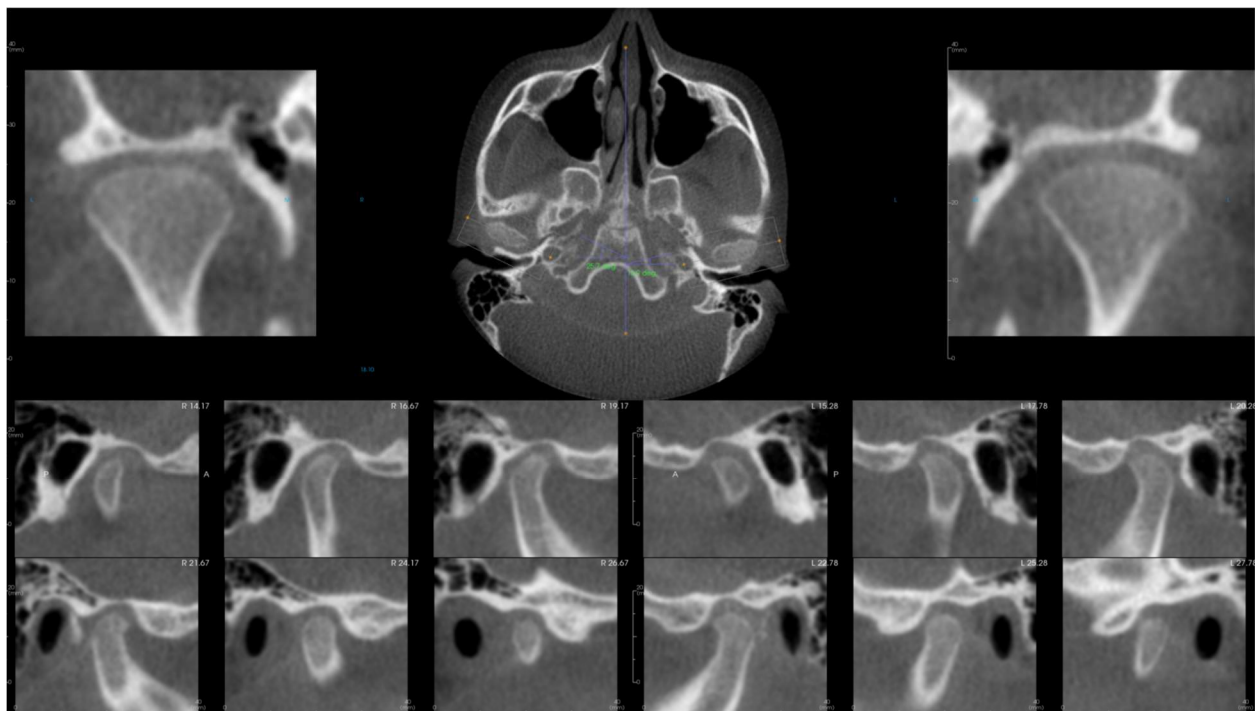
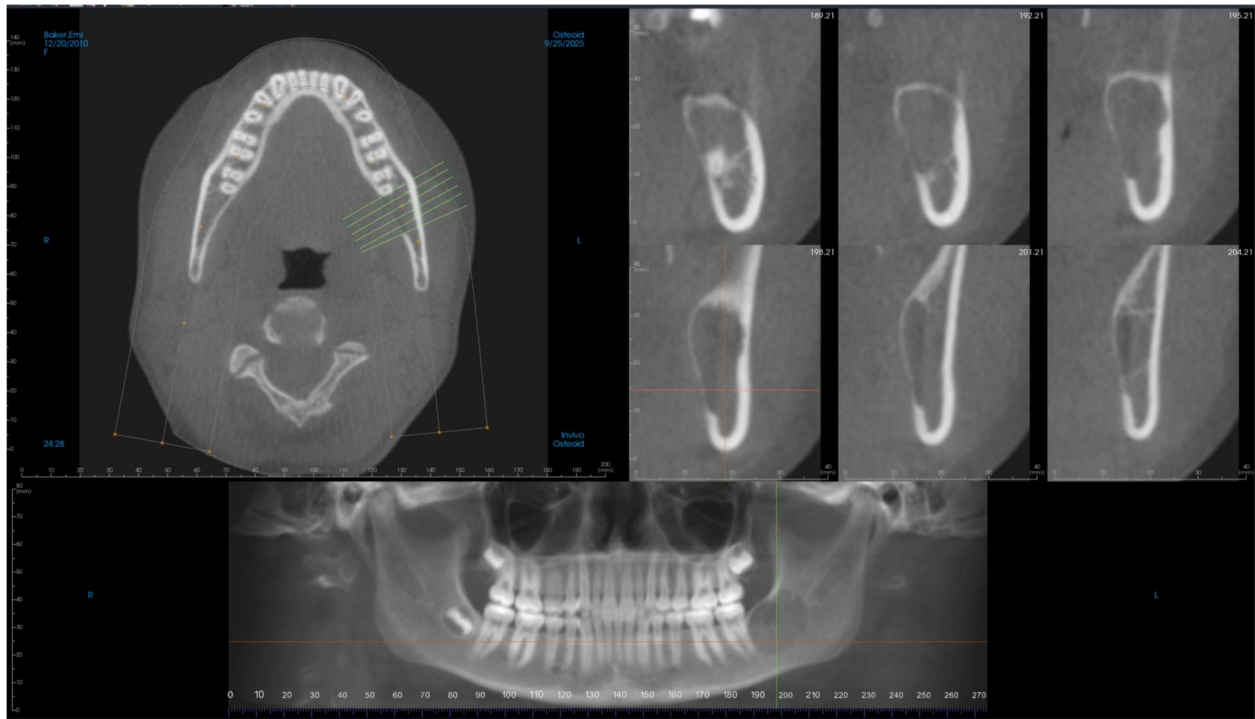
- *Please note that measurements should not be made from any attached images. These are representative slices for reference.*
- *This is a consultative report only and is not intended to be a definitive diagnosis or treatment plan.*

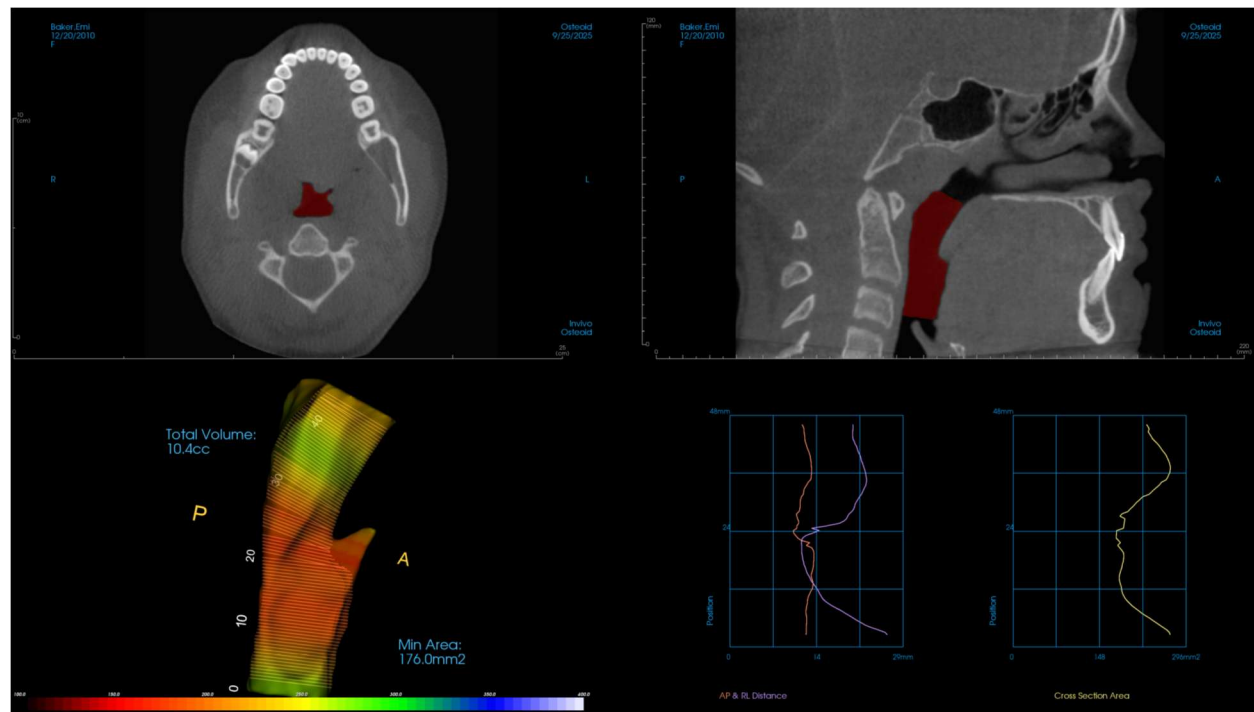


Panoramic reconstruction



Left posterior mandible, radiolucent lesion at site #17





Airway analysis